

See discussions, stats, and author profiles for this publication at: <https://www.researchgate.net/publication/260198655>

Influence of increasing fluoride dose rates on selected liver and kidney enzymes profile in domestic chicken (*Gallus domesticus*)

Article in *The Journal of Animal and Plant Sciences* - January 2014

CITATIONS

13

READS

298

8 authors, including:



Muhammad Sharif Mughal

Government College University, Lahore

105 PUBLICATIONS 515 CITATIONS

SEE PROFILE



Atif Yaqub

Government College University, Lahore

67 PUBLICATIONS 445 CITATIONS

SEE PROFILE



Anjum Khaliq

University of Veterinary and Animal Sciences

77 PUBLICATIONS 1,008 CITATIONS

SEE PROFILE

INFLUENCE OF INCREASING FLUORIDE DOSE RATES ON SELECTED LIVER AND KIDNEY ENZYMES PROFILE IN DOMESTIC CHICKEN (*Gallus domesticus*)

K. M. Anjum, M.S. Mughal^{*}, U. Sayyed^{**}, A. Yaqub^{**}, A. Khalique^{***}, M.A. Rashid^{***}, M. Z. Yousaf[†], and N. Mumtaz^{**†}

Department of Wildlife and Ecology, University of Veterinary and Animal Sciences, Lahore, Pakistan

^{*}Department of Fisheries and Aquaculture, University of Veterinary and Animal Sciences, Lahore, Pakistan.

^{**}Department of Zoology, GC University, Lahore, Pakistan

^{***}Department of Animal Nutrition, University of Veterinary and Animal Sciences, Lahore, Pakistan

[†]Nano-Biotechnology Lab, Department of Advanced Materials, College of Engineering, Peking University, Beijing, China

^{**†}Department of Zoology, University of Education, Bank Road Campus, Lahore, Pakistan

Corresponding author email: raviankhalid@gmail.com

ABSTRACT

Fluoride has been considered to cause hepatic and renal tissue damages in animals and humans. The present study investigated the effect of varying concentrations of fluoride on hepatic and renal enzyme profile in domestic chicken (n=80). Chicken were distributed into 4 groups. Group A was kept unexposed while group B, C and D were exposed to 10, 20 and 30 µg/g body weight of NaF respectively on weekly basis for four weeks. Alkaline phosphatase (ALP), aspartate aminotransferase (AST), alanine amino-transferase (ALT) and bilirubin were determined as indicators of liver function test (LFT), while uric acid was as a parameter for renal function test (RFT). All LFT and RFT parameters showed high values (P< 0.05) after one, two three and four weeks in all groups. 579.4 ± 1.55 , 355.0 ± 2.13 , 246.2 ± 2.45 and 0.83 ± 1.46 were the ALP, AST, ALAT and bilirubin values for LFT and uric acid was 6.74 ± 2.92 in D group at the end of four weeks. All these results indicate the probability of severe effect on the physiology of the liver and kidneys in the exposed birds.

Key words: Fluoride intoxication, domestic chicken, LFT, RFT, bilirubin.

INTRODUCTION

Although fluoride intake is necessary for the development of teeth and body skeleton but requirements are in traces. However, a few recent studies indicated that more fluoride intake might cause toxic effects in animals and human being (Bhatnagar *et al.*, 2011). Fluoride intake (fluorosis) usually occurs in two forms; endemic fluorosis, related to intake of drinking water with high fluoride contents (Li and Cao, 1994) and industrial fluorosis, related to exposure to air rich in fluoride contents (Czerwinski *et al.*, 1988; Grandjean *et al.*, 1985). Fluorosis has been found to cause severe side effects, not only to skeletal parts of the body (Finkelman *et al.*, 1999; Wei, 1979) but also to the soft tissues like brain, liver, kidney and spinal cord (Guan *et al.*, 1998; Wang *et al.*, 2004).

Earlier work by Guan *et al.* (2000) reported that 50-80% of the absorbed fluorides are eliminated by the kidneys indicating the chances of kidney damages due to fluorosis. Liver is the main organ for fluoride detoxification and, therefore, is highly susceptible to the fluoride intoxication (Wang and Li, 2002). Various studies demonstrated that elevated levels of serum hepatic and renal enzymes have been found following fluoride intoxication indicating degenerative and inflammatory damages to the liver and kidney

(Shivashankara *et al.*, 2000; Wang and Li, 2002; Shashi and Thapar, 2001). Other histopathological findings include hyperplasia, dilatations of hepatic sinusoids (Kour *et al.*, 1981), and accumulation of amorphous and crystalline bodies in the hepatocytes around the hepatic vein (Phillips *et al.*, 1934), and in some rare cases the hepatocholan-giocarcinomain (Maurer *et al.*, 1990). It has been found that fluoride intoxication induced hepatic hemangiosarcoma, hepatocellular adenoma and carcinoma, metastatic lung tumors, and Zymbal's gland tumors in rats (Bogdanffy *et al.*, 1995).

Commercial poultry production is being done extensively throughout the Pakistan. Further, management and production varies with the region which might be due to changes in the water and the presence of industrial wastes. Fluoride intoxication could be one of the intoxicants. Therefore, considering the growth of poultry sector and intensification of poultry farms around the urban areas, we hypothesized that higher levels of fluoride can affect the profile of liver and kidney enzymes. Selected serum liver enzymes were; alkaline phosphatase, aspartate aminotransferase, alanine aminotransferase, bilirubin and uric acid and for kidneys. Therefore, objective of current experiment was to evaluate the effect of fluoride intoxication on changes in liver and kidney enzymes of domestic chicken (*Gallus domesticus*).

MATERIALS AND METHODS

Eighty, a day old, domestic chickens (*Gallus domesticus*) were purchased from a local market. Chicks were reared till the age of four weeks before the start of experiment. The experimental protocols were approved by the ethical committee on animal research, GC University, Lahore (GCU).

Experimental Design: The birds were reared at the Animal House, Government College University, Lahore. After adaptability period, chicks were assigned one of the four dietary treatments namely A, B, C and D with 20 chicks per treatment. Group A served as a control group that was not treated with any fluoride intoxication; whereas, in group B, C and D, chicks were injected a weekly dose of NaF 10, 20, and 30 μg per gram of body weight, respectively. Chicks were sacrificed at the end of experiment and blood samples were collected.

Determination of Activities of Enzymes: Blood was collected from wing vein of chicken and then centrifuged at 5,000 rpm for five minutes to harvest the serum that were stored at -20°C till further analysis. At the time of analyses, the serum samples were thawed and concentrations of alkaline phosphatase, aspartate aminotransferase, alanine aminotransferase, bilirubin and uric acid were determined using (MEDPHARM) commercial kits.

Data Analysis: Data, presented as mean \pm S.D, were analyzed using one-way analysis of variance (ANOVA) and Tukey's posthoc multiple comparison test. Data analysis was performed using statistical package SPSS (Version 13.0 SPSS Inc., Chicago, IL, USA) and results were declared significant at $P < 0.05$.

RESULTS AND DISCUSSION

When chicks were exposed to acute fluoride intoxication, higher ($P < 0.05$) values of ALP were observed in all treatment groups. The ALP in control group was reported as 339.2 ± 1.44 . The present study shows that ALP increased in an increased dose of fluoride manner, in group B ALP was 444.8 ± 2.32 ; whereas 507.1 ± 1.54 and 579.4 ± 1.55 was observed ALP in group C and D. These results clearly indicate that the ALP was higher in those groups receiving the higher dose of fluoride intoxicant as shown in Table 1.

The serum AST also increased ($P < 0.05$) with the increasing dose of fluoride. In control group, AST was 198.4 ± 2.44 ; whereas, in group B concentration was 268.2 ± 1.90 . Highest values 310.9 ± 2.12 and 355.0 ± 2.13 of AST were observed in C and D groups respectively. Furthermore, serum ALT was 168.7 ± 1.55 , 204.7 ± 4.18 , 220.0 ± 3.56 and 246.2 ± 2.45 in the control

B, C and D groups respectively shown (Table 1 & Fig1). The bilirubin level in control was 0.52 ± 0.04 U/L which increased in all treatment groups. The highest level of bilirubin (0.83 ± 1.46 U/L) was reported in the group D at the end of one month exposure to NaF as shown in Fig 2.

Increased serum bilirubin level indicates the impairment of liver functions as it is generally considered as a true test for proper liver functioning. It reflects the liver's ability to take up and secrete bilirubin into the bile. The increase in ALP, AST, ALT and bilirubin was due to the degeneration and necrosis of liver cells. Shashi and Thapar (2001) reported that necrosis depends on the time of fluoride exposure. They showed that hepatic cell necrosis and other structural changes were more pronounced in the rabbits exposed to fluoride intoxication for three months than those exposed for one month. Similar study was conducted in human by Michael *et al.* (1996) to investigate the effect of high dose of fluoride intake from drinking water on some soft tissues and found that high levels of fluoride disturbed the normal ALT and AST values. The elevated ALP, AST, ALT and bilirubin is an indication of the impairment of liver functions. Most of the liver function enzymes were found abnormal in the children having skeletal fluorosis (Shivashankara *et al.*, 2000). All these studies support our present findings of higher AST, ALP, ALT and bilirubin levels in the blood serum of chicken exposed to high doses of fluoride.

RFT parameter, uric acid also increased ($P < 0.05$) in treatment groups. The uric acid level in the control was 3.63 ± 2.45 ; whereas 4.54 ± 2.86 , 5.55 ± 1.88 and 6.74 ± 2.92 (Table 1) were the reported values of uric acid after one month in group A, B, C and D respectively as shown in Fig 2. High uric acid indicates the impairment in the kidney functions as there are several evidences that hyperuricemia is the causative agent of kidney diseases (Sowers, 2004). High uric acid also aids in the development of other diseases like the albuminuria, microvascular disease, glomerulosclerosis, and tubulointerstitial fibrosis (Nakagawa *et al.*, 2002). There are evidences that uric acid is a potent risk factor for kidneys in normal population as well as the population having kidney disease due to immunoglobulin A (IgA) nephropathy. A comparative study also indicate that hyperuricemia have more severe effects to the kidneys than proteinuria and make the kidneys less efficient and develop the kidney insufficiency (Sanchez-Lozada *et al.*, 2005). High uric acid is a prediction of hypertension, metabolic syndrome (Masuo *et al.*, 2003), diabetes (Nakanishi *et al.*, 2003) and stroke (Bos *et al.*, 2006). The present study provides us informations about the serum enzymes which are basic indicators of liver and kidney functioning at different fluoride exposure. It will be helpful to devise some strategies to protect the liver, kidneys and skeleton before they are fully damaged and get irreversible loss.

Table 1. Effect of increasing levels of fluoride on liver and kidney serum enzymes of domestic chicken.

	Treatment Groups ¹			
	A	B	C	D
ALP	339.2 ^a ± 1.14	444.8 ^b ± 2.32	507.1 ^c ± 1.54	579.4 ^d ± 1.55
AST	198.4 ^a ± 2.44	268.2 ^b ± 1.90	310.9 ^c ± 2.12	355.0 ^d ± 2.13
ALT	168.7 ^a ± 1.55	204.7 ^b ± 4.18	220.0 ^c ± 3.56	246.2 ^d ± 2.45
Bilirubin	0.52 ^a ± 3.20	0.61 ^b ± 3.21	0.65 ^c ± 2.58	0.83 ^d ± 1.46
Uric Acid	3.63 ^a ± 2.45	4.54 ^b ± 2.86	5.55 ^c ± 1.88	6.74 ^d ± 2.92

^{a-d} within a row means for each variable without a common superscript differs significantly at P < 0.05.

¹ Treatments: Group A (control) without fluoride; whereas, Group B, C and D, chicks were injected a weekly dose of NaF 10, 20, and 30 µg per gram of body weight, respectively.

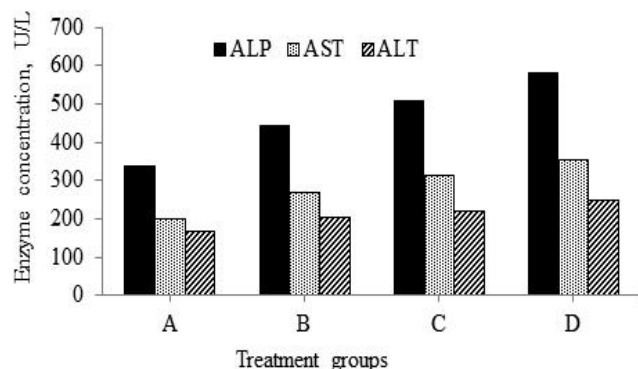


Figure 1. Means ALP, AST and ALT of liver function enzymes injected increasing dose rate of fluoride in domestic chicken: Group A (control) without fluoride, and a dose of NaF 10, 20, and 30 µg/g of BW injected to chickens on a weekly basis in treatment Group B, C and D, respectively. Means for each treatment are presented as: ALP; solid bars, AST; dots, and ALT; upward cross bars.

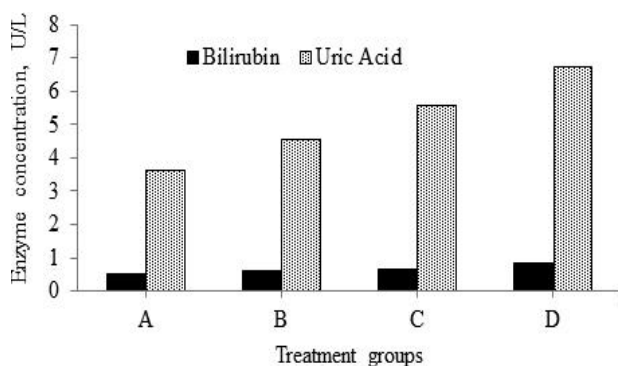


Figure 2. Means of bilirubin and uric acid injected increasing dose rate of fluoride in domestic chicken: Group A (control) without fluoride, and a dose of NaF 10, 20, and 30 µg/g of BW injected to chickens on a weekly basis in treatment Group B, C and D, respectively. Means for each treatment are presented as: Bilirubin; solid bars, and Uric Acid; dots.

REFERENCES

- Bhatnagar, A., E. Kumar, and M. Sillanpää (2011). Fluoride removal from water by adsorption—a review. *Chem. Eng. J.* 171(3):811-840.
- Bogdanffy, M. S., T. G. Makovec, and S. R. Frame (1995). Inhalation oncogenicity bioassay in rats and mice with vinyl fluoride. *Toxicol. Sci.* 26(2):223-238.
- Bos, M. J., P. J. Koudstaal, A. Hofman, J. C. Witteman, and M. M. Breteler (2006). Uric Acid Is a Risk Factor for Myocardial Infarction and Stroke The Rotterdam Study. *Stroke* 37(6):1503-1507.
- Czerwinski, E., J. Nowak, D. Dabrowska, A. Skolarczyk, B. Kita, and M. Ksiezyc (1988). Bone and joint pathology in fluoride-exposed workers. *Arch. Environ. Health* 43(5):340-343.
- Finkelman, R. B., H. E. Belkin, and B. Zheng (1999). Health impacts of domestic coal use in China. *Proc. Natl. Acad. Sci.* 96(7):3427-3431.
- Grandjean, P., K. Juel, and O. M. Jensen (1985). Mortality and cancer morbidity after heavy occupational fluoride exposure. *Am. J. Epidemiol.* 121(1):57-64.
- Guan, Z.-Z., Y.-N. Wang, K.-Q. Xiao, D.-Y. Dai, Y.-H. Chen, J.-L. Liu, P. Sindelar, and G. Dallner (1998). Influence of chronic fluorosis on membrane lipids in rat brain. *Neurotoxicol. Teratol.* 20(5):537-542.
- Guan, Z.-Z., K.-Q. Xiao, X.-Y. Zeng, Y.-G. Long, Y.-H. Cheng, S.-F. Jiang, and Y.-N. Wang (2000). Changed cellular membrane lipid composition and lipid peroxidation of kidney in rats with chronic fluorosis. *Arch. Toxicol.* 74(10):602-608.
- Kour, K., M. Koul, and R. Koul (1981). Histological Changes in Liver Following Sodium Fluoride Ingestion. *Fluoride* 14(3):119-123.
- Li, J. and S. Cao (1994). Recent studies on endemic fluorosis in China. *Fluoride* 27(3):125-128.
- Masuo, K., H. Kawaguchi, H. Mikami, T. Ogihara, and M. L. Tuck (2003). Serum uric acid and plasma norepinephrine concentrations predict

- subsequent weight gain and blood pressure elevation. *Hypertension* 42(4):474-480.
- Maurer, J. K., M. C. Cheng, B. G. Boysen, and R. L. Anderson (1990). Two-year carcinogenicity study of sodium fluoride in rats. *J. Natl. Cancer Inst.* 82(13):1118-1126.
- Michael, M., V. V. Barot, and N. Chinoy (1996). Investigations of soft tissue functions in fluorotic individuals of North Gujarat. *Fluoride* 29:63-71.
- Nakagawa, T., M. Mazzali, D.-H. Kang, J. Kanellis, S. Watanabe, L. G. Sanchez-Lozada, B. Rodriguez-Iturbe, J. Herrera-Acosta, and R. J. Johnson (2002). Hyperuricemia causes glomerular hypertrophy in the rat. *Am. J. Nephrol.* 23(1):2-7.
- Nakanishi, N., M. Okamoto, H. Yoshida, Y. Matsuo, K. Suzuki, and K. Tataru (2003). Serum uric acid and risk for development of hypertension and impaired fasting glucose or Type II diabetes in Japanese male office workers. *Eur. J. Epidemiol.* 18(6):523-530.
- Phillips, P. H., E. B. Hart, and G. Bohstedt. (1934). Chronic toxicosis in dairy cows due to ingestion of fluorine. Pages 1-30 in *Res. Bulle.* 123, University of Wisconsin Agricultural Experimental Station.
- Sanchez-Lozada, L. G., E. Tapia, J. Santamaria, C. Avila-Casado, V. Soto, T. Nepomuceno, B. Rodriguez-Iturbe, R. J. Johnson, and J. Herrera-Acosta (2005). Mild hyperuricemia induces vasoconstriction and maintains glomerular hypertension in normal and remnant kidney rats. *Kidney Int.* 67(1):237-247.
- Shashi, A. and S. Thapar (2001). Histopathology of fluoride-induced hepatotoxicity in rabbits. *Fluoride* 34(1):34-42.
- Shivashankara, A., Y. S. Shankara, S. H. Rao, and P. G. Bhat (2000). A clinical and biochemical study of chronic fluoride toxicity in children of Kheru Thanda of Gulbarga district, Karnataka, India. *Fluoride* 33(2):66-73.
- Sowers, J. R. (2004). Insulin resistance and hypertension. *Am. J. Physiol-Heart C.* 286(5):H1597-H1602.
- Wang, A. G., T. Xia, R. Ru, J. Yuan, X. Chen, K. Yang, and K. Yang (2004). Antagonistic effect of selenium on oxidative stress, DNA damage, and apoptosis induced by fluoride in human hepatocytes. *Fluoride* 37(2):107-116.
- Wang, W. and Y. Li (2002). Environmental epidemiology of fluorine and its effects on health. *Soil Environ. Sci.* 11(4):383-387.
- Wei, Z. (1979). Endemic food-borne fluorosis in Guizhou, China. *Prev Med J* 13:148-151.